

**AIS****PennHIP**

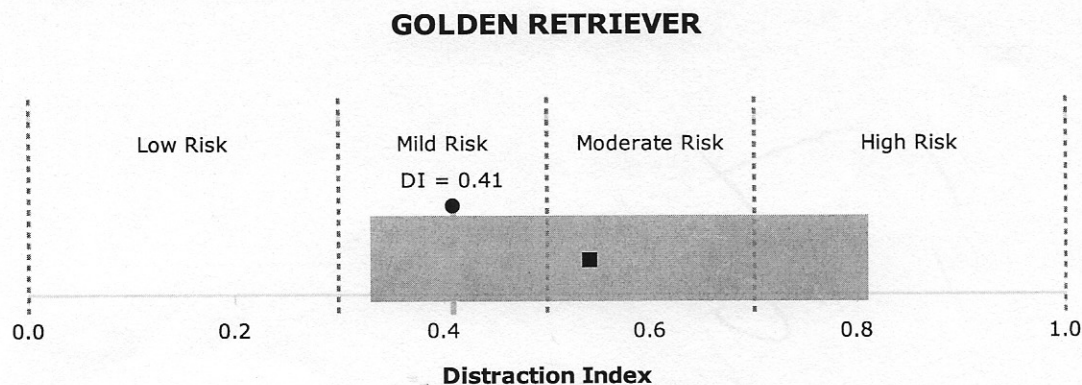
(877) 727-6800

www.antechimagingervices.com

Owner's Copy

**PennHIP Report****Referring Veterinarian:** Dr Barak Benaryeh**Clinic Name:** Spicewood Springs Veterinary Hospital**Email:**  
drbenaryeh@spicewoodanimalhospital.com**Clinic Address:** 4606 Spicewood Springs Road

Austin, TX 78759

**Phone:** (512) 345-2727**Fax:**(512) 345-7611**Patient Information****Client:** Tchakarov, Danail**Tattoo Num:****Patient Name:** Sarah**Patient ID:** 33797**Reg. Name:** Sarah of Berkeley**Registration Num:** SS00875201**PennHIP Num:** 120232**Microchip Num:** 990000000850464**Species:** Canine**Breed:** GOLDEN RETRIEVER**Date of Birth:** 31 May 2017**Age:** 14 months**Sex:** Female**Weight:** 56.2 lbs/25.5 kgs**Date of Study:** 16 Jul 2018**Date Submitted:** 16 Jul 2018**Date of Report:** 19 Jul 2018**Findings****Distraction Index (DI):**Right DI = 0.38, Left DI = 0.41.**Osteoarthritis (OA):**No radiographic evidence of OA for either hip.**Cavitation/Other Findings:**None.**Interpretation****Distraction Index (DI):**The laxity ranking is based on the hip with the greater laxity (larger DI). In this case the DI used is 0.41.**OA Risk Category:**The DI is between 0.31 and 0.49. This patient is at mild risk for hip OA.**Distraction Index Chart:****Breed Statistics:**This interpretation is based on a cross-section of 19170 canine patients of the GOLDEN RETRIEVER breed in the AIS PennHIP database. The gray strip represents the central 90% range of DIs (0.33 - 0.81) for the breed. The breed average DI is 0.54 (solid square). The patient DI is the solid circle (0.41).