

PennHIP Report

Referring Veterinarian: Dr Matthew Dikeman
 Email: bahxrays@gmail.com

Clinic Name: Brittmoore Animal Hospital
 Clinic Address: 1236 Brittmoore Rd.
 Houston, TX 77043
 Phone: (713) 468-8253
 Fax: (713) 468-8995

Patient Information

Client: Hickman, Kay
 Patient Name: Lacey
 Reg. Name: Lacey of Weather by Goldens
 PennHIP Num: 129232
 Species: Canine
 Date of Birth: 04 Jul 2018
 Sex: Female
 Date of Study: 17 Apr 2019
 Date of Report: 22 Apr 2019

Tattoo Num:
 Patient ID: 107777
 Registration Num: SS06874304
 Microchip Num: 956000010140757
 Breed: GOLDEN RETRIEVER
 Age: 9 months
 Weight: 55 lbs/24.9 kgs
 Date Submitted: 17 Apr 2019

Findings

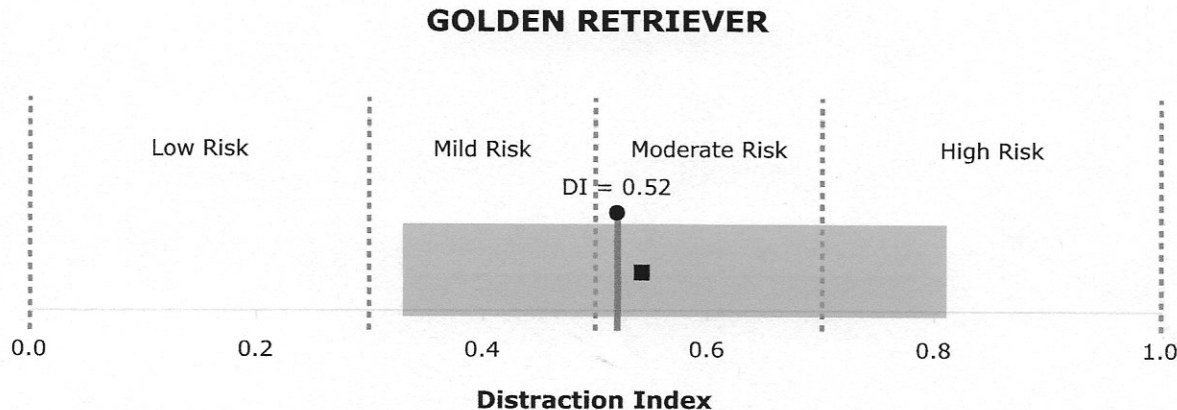
Distraction Index (DI): Right DI = 0.52, Left DI = 0.45.
 Osteoarthritis (OA): **No radiographic evidence of OA for either hip.**
 Cavitation/Other Findings: No cavitation present.

Interpretation

Distraction Index (DI): The laxity ranking is based on the hip with the greater laxity (larger DI). In this case the 0.52.

OA Risk Category: The DI is between 0.50 and 0.69. This patient is at moderate risk for hip OA.

Distraction Index Chart:



BREED STATISTICS: This interpretation is based on a cross-section of 19967 canine patients of the GOLDEN RETRIEVER breed in the AIS PennHIP database. The gray strip represents the central 90% range of DIs (0.33 - 0.69).