



\*For best printing results please use Chrome or IE.  
Doctor's Copy

### PennHIP Report

**Referring Veterinarian:** Dr Gerald Blackburn  
**Email:** gcah@comcast.net

**Clinic Name:** Gentle Care Animal Hospital (TN)  
**Clinic Address:** 2958 Covington Pike  
Memphis, TN 38128

**Phone:** (800) 872-1001

**Fax:** (901) 273-2274

### Patient Information

**Client:** KOVACHEV, EVGENI

**Patient Name:** ELLIOT OF BERKELEY

**Reg. Name:** ELLIOT OF BERKELEY

**PennHIP Num:** 111453

**Species:** Canine

**Date of Birth:** 17 Mar 2015

**Sex:** Male

**Date of Study:** 18 Sep 2017

**Date of Report:** 20 Sep 2017

**Tattoo Num:**

**Patient ID:** 15778-ELLIOTT OF BERKELEY

**Registration Num:** SR87329708

**Microchip Num:**

**Breed:** GOLDEN RETRIEVER

**Age:** 30 months

**Weight:** 70 lbs/31.8 kgs

**Date Submitted:** 18 Sep 2017

### Findings

**Distraction Index (DI):** Right DI = 0.46, Left DI = 0.46.

**Osteoarthritis (OA):** No radiographic evidence of OA for either hip.

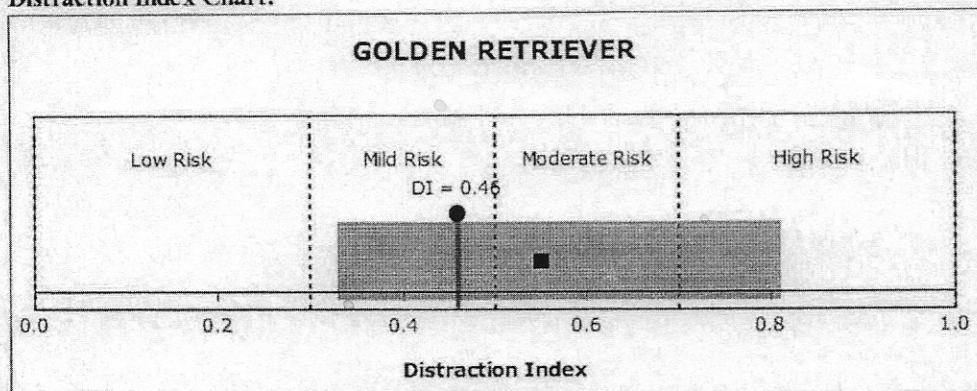
**Cavitation/Other Findings:** None.

### Interpretation

**Distraction Index (DI):** The laxity ranking is based on the hip with the greater laxity (larger DI). In this case the DI used is 0.46.

**OA Risk Category:** The DI is between 0.31 and 0.49. This patient is at mild risk for hip OA.

**Distraction Index Chart:**



**Breed Statistics:** This interpretation is based on a cross-section of 18032 canine patients of the GOLDEN